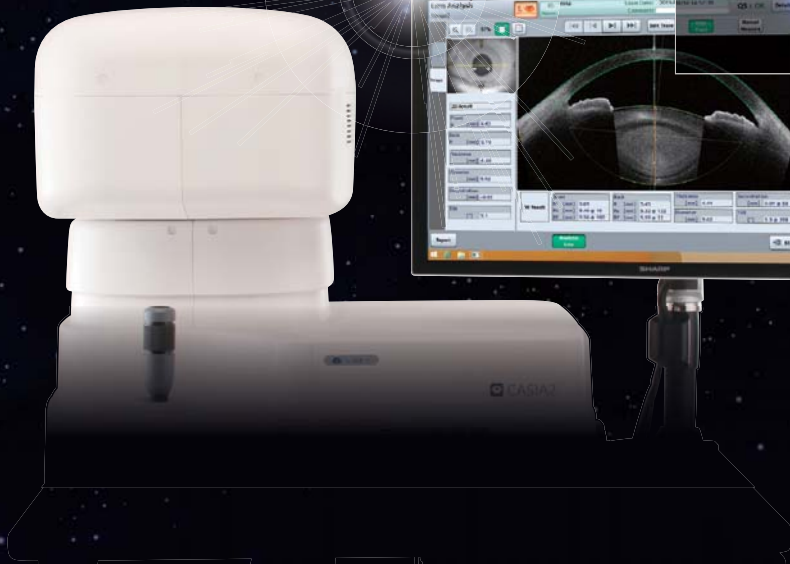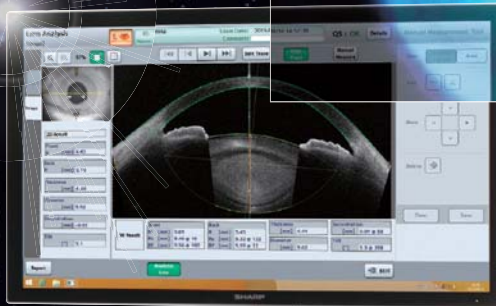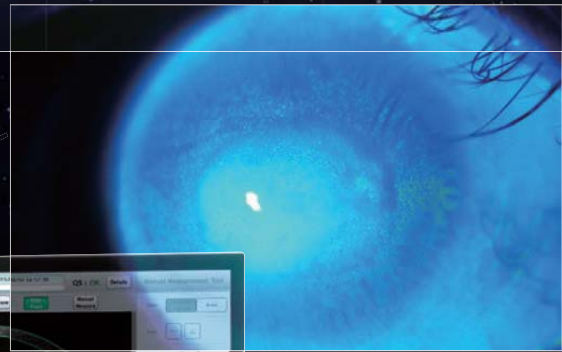
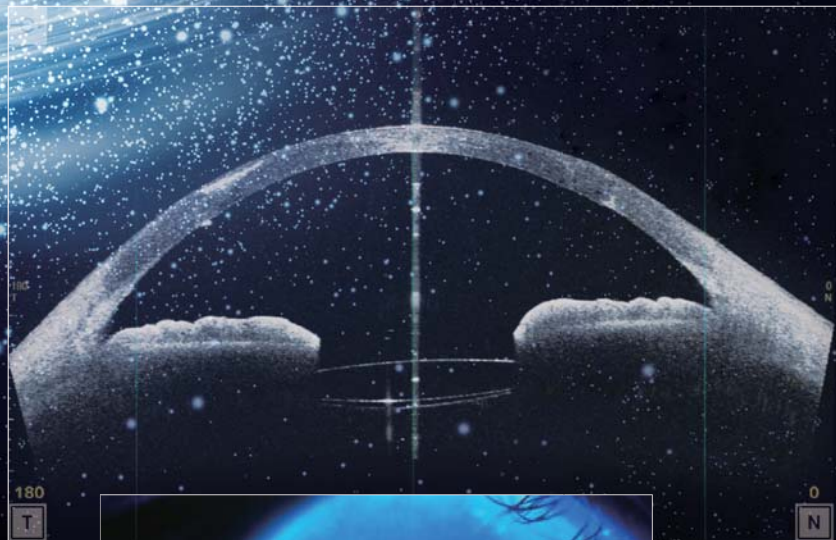




Cornea/Anterior Segment OCT

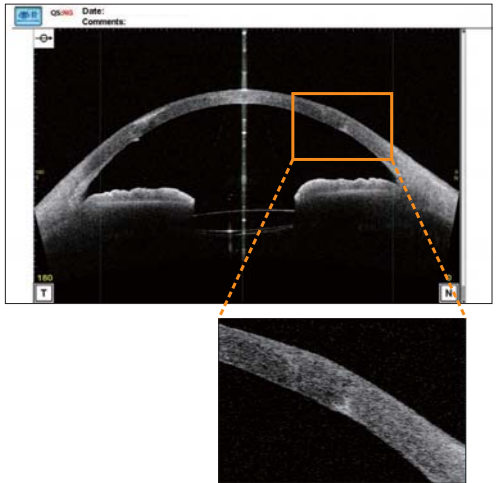
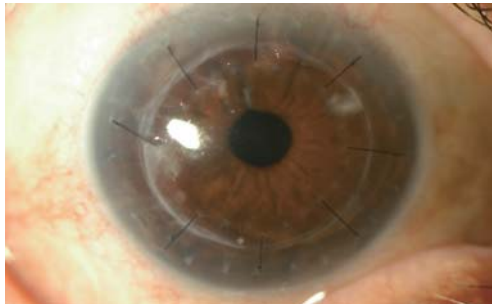
CASIA2

User Experience



CASIA2 User Experience

Case#1 Post Penetrating Keratoplasty



Tokyo Medical University /
Kohsei Chuo General Hospital

Hideki Mori MD, PhD

Almost eight years have passed since the anterior segment OCT was launched.*

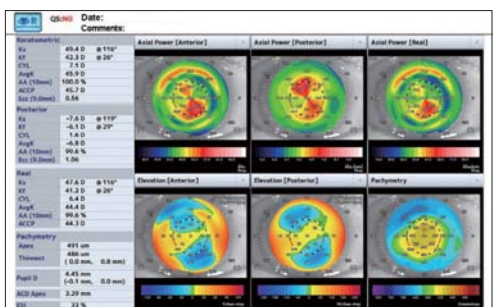
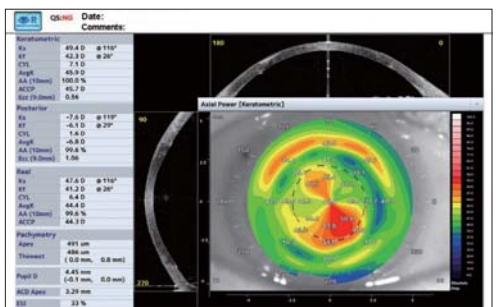
The Anterior Segment OCT SS-1000 CASIA which I have worked on from the initial development, has now become CASIA2, whose measurement area and functionality has improved. In this user experience, I summarized cases in which CASIA2 was beneficial - mainly corneal transplantation cases. I also introduced an interesting use of hard contact lenses and cornea for reference.

*At the time of writing

After a penetrating keratoplasty, it is important to observe the transparency of the graft and the wound healing.

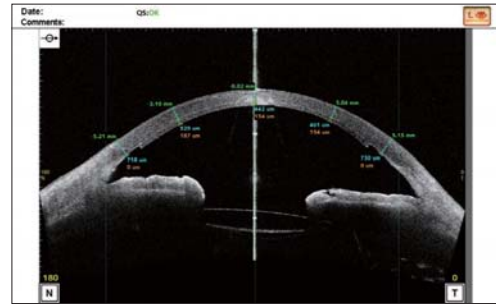
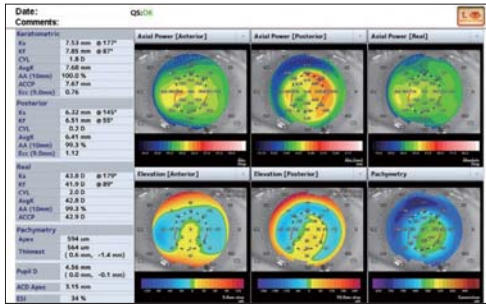
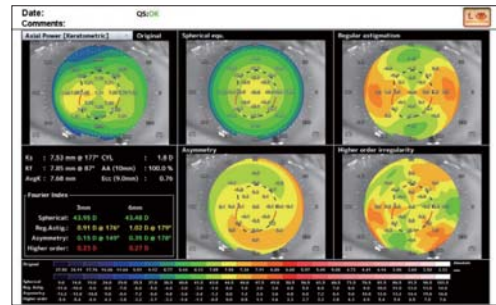
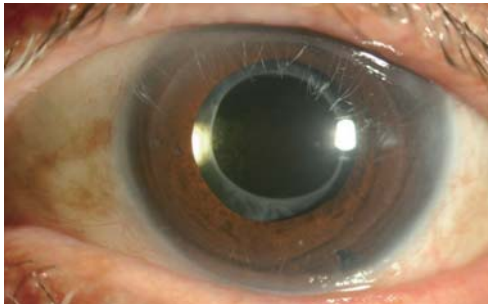
By using CASIA2, the junctions of the suture wound can be observed in detail and the conditions of the anterior chamber angle can be simultaneously examined.

In tomographic images, when a multi-image is selected, it is possible to see the image from 16 directions at once.



After a penetrating keratoplasty, evaluation of the corneal shape is essential as post-op corneal astigmatism greatly affects the visual function. The topographic function of CASIA2 has accurate repeatability toward higher-order corneal irregular astigmatism. In the corneal shape evaluation, the 6-map display enables numerous maps and allows customized settings.

Case#2 Post-DSAEK

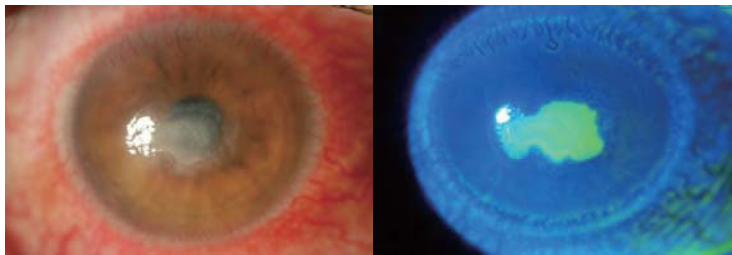


After DSAEK, since post-op corneal astigmatism is less likely to occur, a better visual function can be obtained. The upper images in the 6 maps show axial power. Corneal irregular astigmatism is seen more in the posterior surface than in the anterior, but seen in Real power, the posterior surface is not greatly affected. The right image on the bottom row shows a Pachy Map, and it is possible to evaluate distribution of corneal thickness combine recipient with donor.

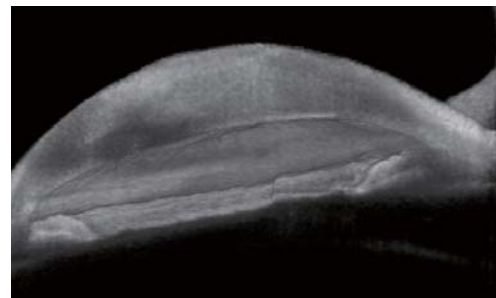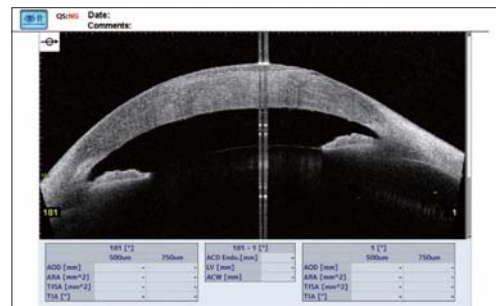
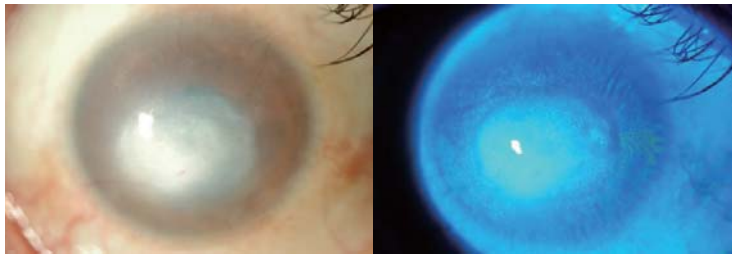If the anterior corneal shape is further analyzed by Fourier analysis, it is possible to evaluate irregular corneal astigmatism with asymmetry astigmatic components and higher-order irregularity. To evaluate graft thickness, the Flap Tool is convenient as it can evaluate the donor thickness. Currently, analysis is still done manually but is expected to become an automatic function in the future.

Case#3 Infectious Keratitis

1 week after treatment



5 months after treatment

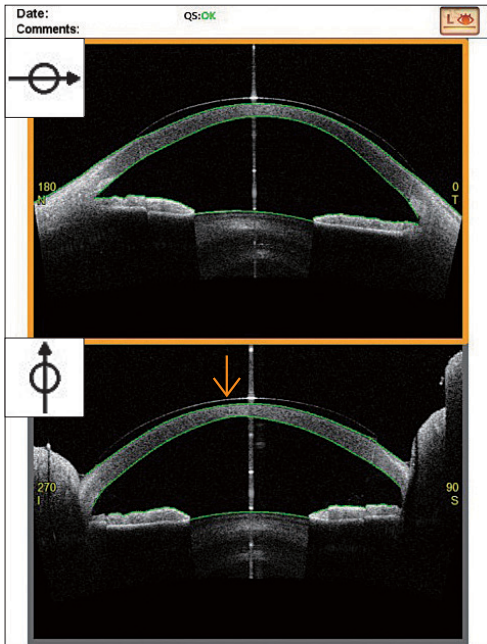


In this case of infectious keratitis, Acanthamoeba was detected in the antigen test. Since it took a long time to settle the keratitis, the cornea suffered severe opacity. Also during treatment, the patient developed iritis; therefore a secondary glaucoma was anticipated. Before the corneal transplantation, evaluation of the anterior chamber angle was necessary.

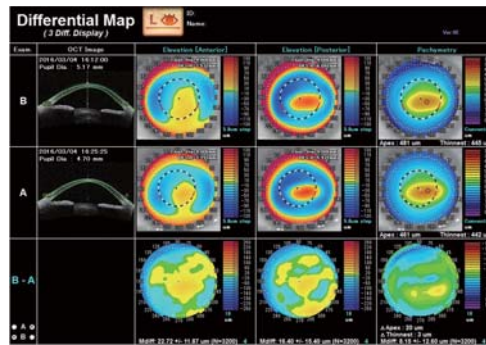
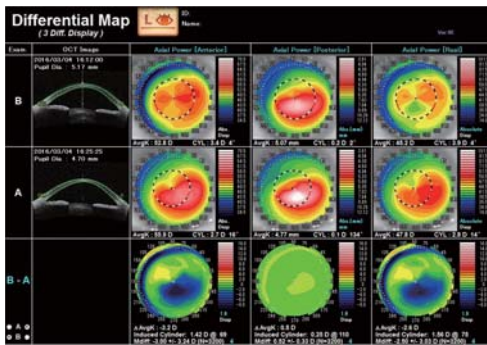
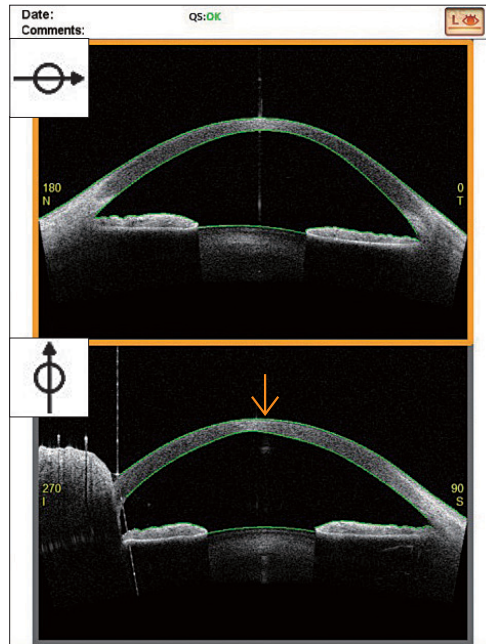
With the severe corneal opacity, it was impossible to evaluate with an ordinary gonioscope, but using CASIA2, screening of the angle closure in the tomographic images and Angle View was possible. A secondary glaucoma after the corneal transplant can affect prognosis, so we can conclude that angle closure screening is a significant test.

Case#4 Changes of Corneal Shape after Removing Hard Contact Lenses

Wearing HCL



15 minutes after removing HCL



With the CASIA2, it is possible to evaluate corneal shape while wearing hard contact lenses (HCL).

In this case, an OCT tomographic image of keratoconus eye compares wearing HCL with HCL removed.

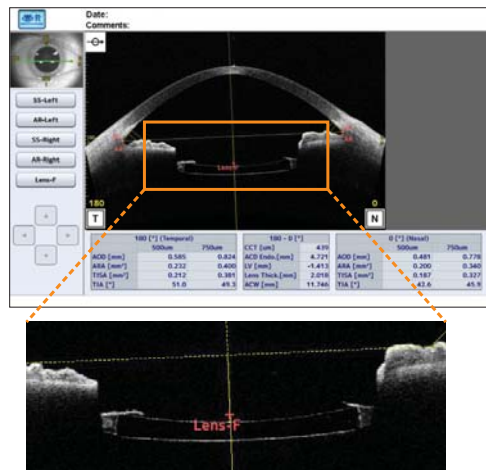
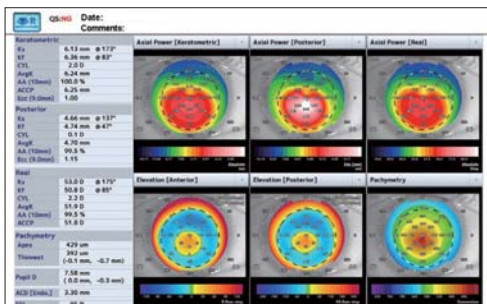
While wearing HCL, the anterior cornea is getting spherical, but after removal, the corneal shape goes back to its original keratoconic shape.

The corneal shape changes, between wearing HCL and removal can be clearly seen in the Differential Map.

The images in the left map show the changes of the Axial Map; the left column shows changes of the anterior Axial Power, the center column shows the posterior Axial Power and the right column shows Real Power. The upper row images show changes during HCL wearing, the center row shows changes after removing the HCL, and the bottom row images show the Power changes. In terms of the Power change, the change in the anterior cornea is significant but that of the posterior is small.

The right map images show changes in the Elevation Map and the Pachy Map. After removing the HCL, the center of the anterior surface of cornea is in the anterior displacement, and so is the posterior surface of cornea. After removing the HCL, the corneal thickness below the center is increasing.

Case#5 Cataract Surgery with Keratoconus Eye



Cataract surgery with keratoconus eye tends to be difficult. One of the problems is IOL power calculation. By using CASIA2, it is possible to acquire an IOL power calculation based on accurate corneal shape data. In this case, the post-op vision was 0.8 (1.0 x -1.0D), and it was an expected value. We could see IOL is a minus lens, and is concave meniscus lens in the tomographic image.

CASIA2 User Experience



Department of Ophthalmology,
Faculty of Medicine, University of Tsukuba

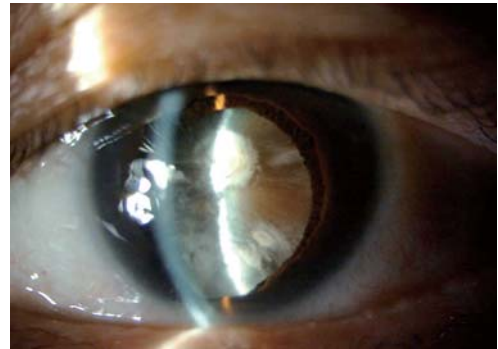Yuta Ueno MD

In 2008, the SS-1000 CASIA was introduced as the first Anterior Segment 3D OCT in the world. It had a huge impact on visualizing not only the clear cornea but also opaque tissue such as muddy cornea, conjunctiva, sclera, iris and angle recess which has led to innovation in a number of clinical fields including cataract, glaucoma, refractive surgery and corneal transplantation. 7 years later, the CASIA2 has emerged as the next-generation Anterior Segment OCT. With the CASIA2, the imaging performance is greatly improved in terms of an expanded measurement range of depth to 13mm, which has made it possible to visualize the anterior and posterior surface of a crystalline lens to detect lens opacity and to perform lens shape analysis.

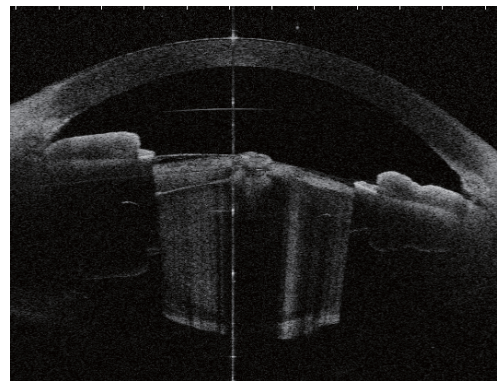
TOMEY OPHTHALMOLOGY NEWS VOL.53
Extracted from [User Experience of Anterior Segment OCT CASIA2]

Case#1 Anterior Capsular Calcification (Traumatic Cataract)

Anterior segment image

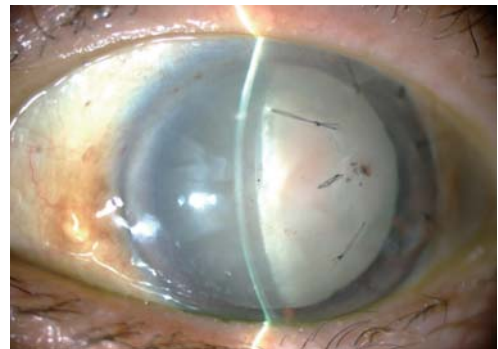


CASIA2

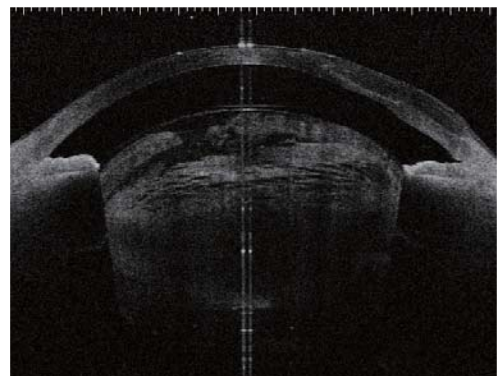


Case#2 Mature Cataract

Anterior segment image

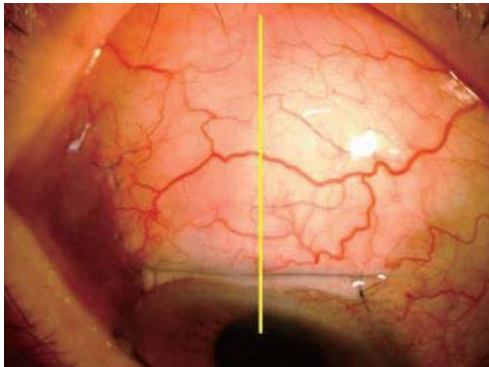


CASIA2

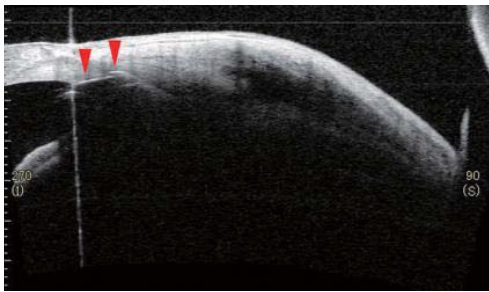


Case#3 EX-PRESS® Glaucoma Shunt Surgery (Post-op 4M)

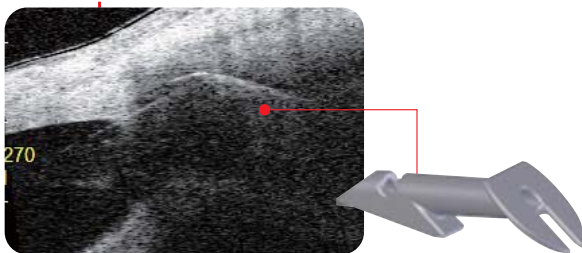
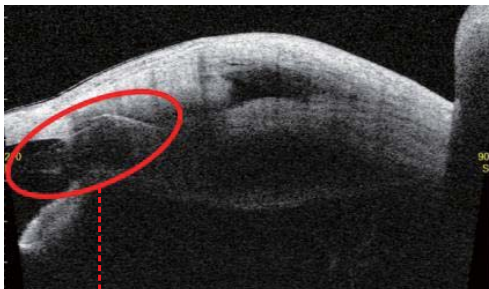Anterior segment image



SS-1000 CASIA



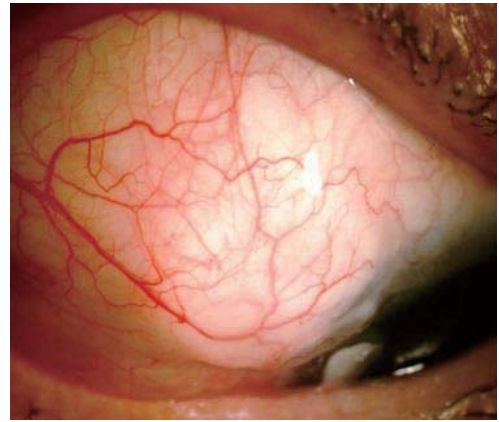
CASIA2



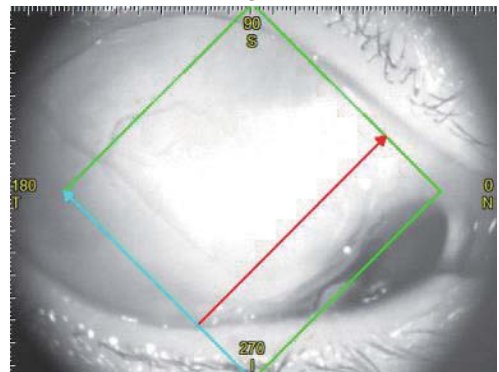
With the SS-1000 CASIA, the internal structure of the filtering bleb and the position of the EX-PRESS® glaucoma shunt (red arrow head) can be observed. With the CASIA2, the EX-PRESS® shunt (red circle) is more clearly visualized, and the depth information including the sub-scleral flap and the ciliary body can be observed.

Case#4 Trabeculectomy (Post-op 3M)

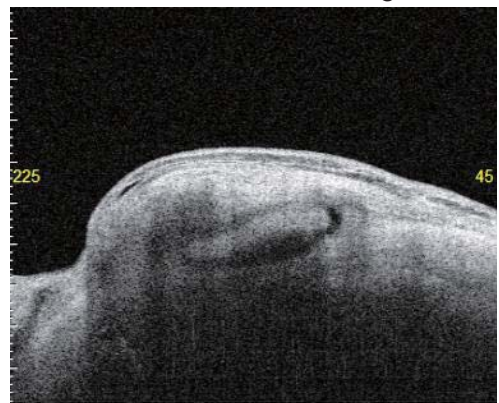Anterior segment image



CASIA2 CCD image



CASIA2 Cross sectional image



The imaging sections using "bleb" mode can be adjusted by 15 degrees step in addition to the vertical and horizontal directions. Even in surgery performed at a diagonal angle, it is possible to measure with the section crossing the scleral flap, and becomes easier to observe the filtration openings on both sides of the flap.

Specifications

[Body]

Resolution	Axial (Depth)	10µm or less (in tissue)
	Transverse	30µm or less (in tissue)
Scan rate		50,000 A scans / second
Scan range	Depth	13mm
	Transverse	Radial Scan: φ16mm Raster Scan: 12mm×12mm
Stroke range of moving section		40mm(Y axis); 88mm(X axis); 45mm(Z axis)
Stroke range of chin rest		70mm
Dimensions and weight		530(W)×560(D)×455(H)mm / approx. 33kg
Type of light source		Swept laser source
Wavelength		1,310nm
Output power		Less than 6mW

[Power source]

Voltage	100 - 240V AC
Frequency	50/60Hz
Power consumption	170VA

[External HDD]

Capacity	8TB
----------	-----

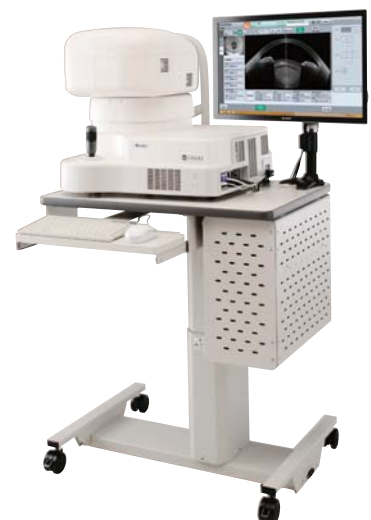[Touch panel LCD monitor]

Display	20 inch touch panel LCD monitor (Screen resolution 1920 x 1080)
---------	--

[Workstation computer]

OS	Windows®8.1 64bit
CPU	Intel® Core i7 processor
Memory	8GB
SSD	128MB
Data output	Printer (LAN/USB)

Specifications are subject to change without notice.
Any products mentioned herein are registered trademarks
of their respective owners.



Website for Medical Staff

PRO +

For Ophthalmology Professionals



Visit this site to view detailed product information,
watch promotion videos and a lot more.

<http://pro.tomey.com>



Tomey Corporation [Asia-Pacific]

2-11-33 Noritakeshinmachi
Nishi-ku, Nagoya, 451-0051, Japan
Tel: ++81-52-581-5327
Fax: ++81-52-561-4735
E-mail: intl@tomey.co.jp

Tomey GmbH [Europe]

Wiesbadener Straße 21
90427 Nürnberg, Germany
Tel: ++49 911-9385462-0
Fax: ++49 911-9385462-20
E-mail: info@tomey.de

For more information, visit our web site

<http://www.tomey.com>